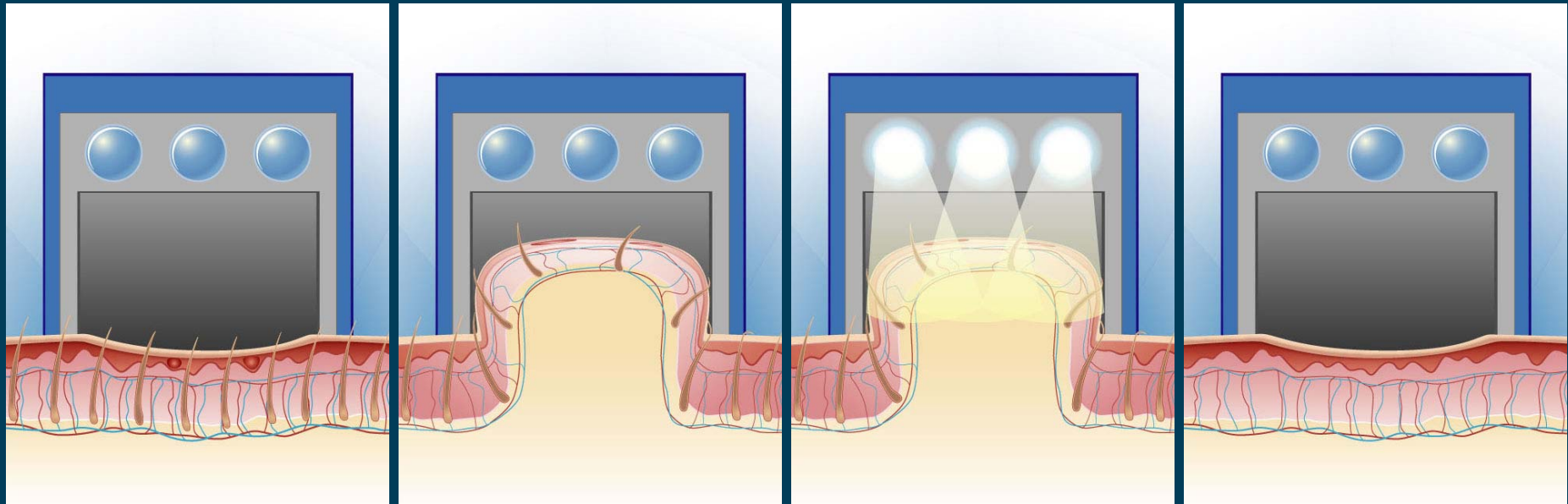


Photopneumatic Therapy™ (PPx™)

Workshop Presentation

AESTHERA™

> Photopneumatic Technology – The Mechanism



- Hand piece is placed on treatment area

- Targets elevated closer to skin's surface

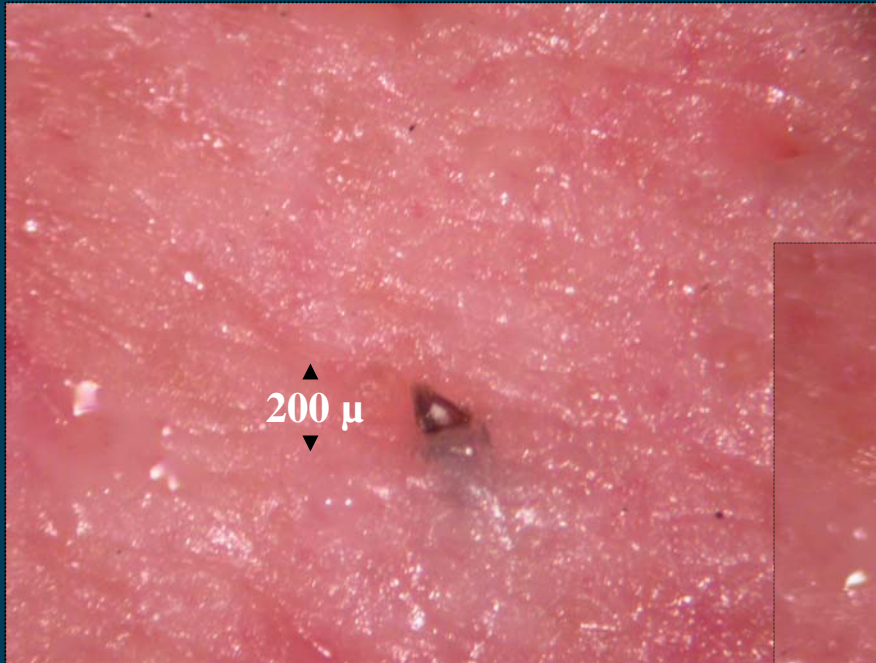- Blood concentration reduced

- Melanin concentration reduced

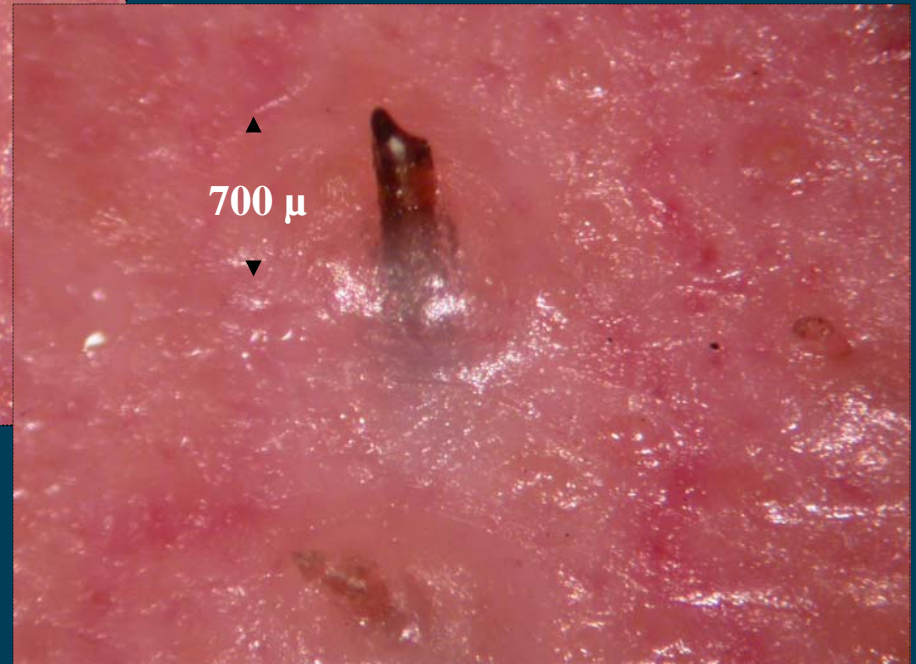
- Light applied to treatment area

- Targets are safely and painlessly destroyed

> PPx elevates targets by 500 μ

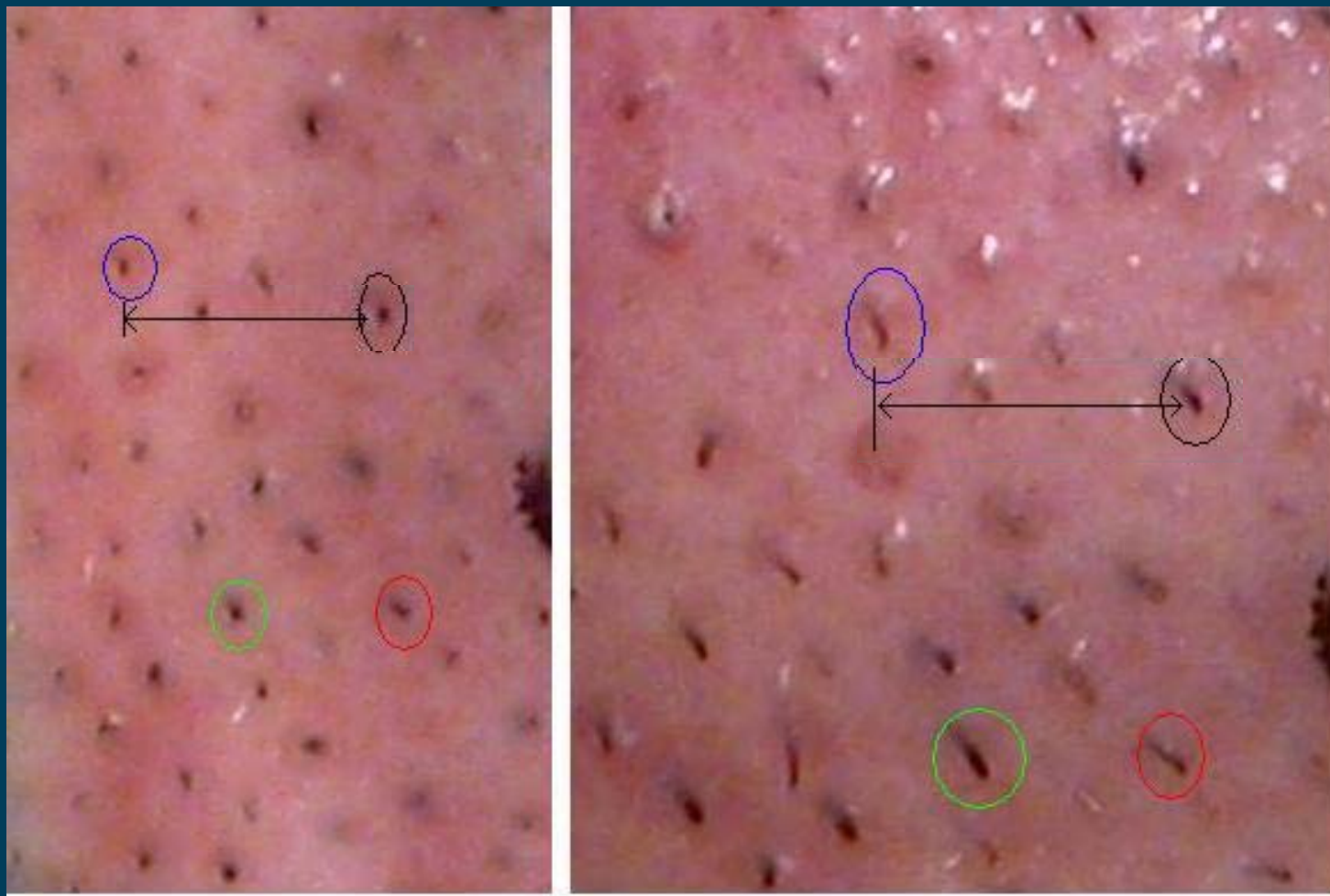


Hair: Pre- Pneumatic Pressure



Hair: During Pneumatic Pressure

> PPx technology pushes target outward and stretches the skin



← 110 pixels

← 135 pixels


> Clinical Outcomes - Hair Removal

Before PPx Therapy



Left Arm before Treatment

After PPx Therapy




4 months post 2nd Treatment

Photographs courtesy Dr. Vic Narurkar, San Francisco, CA

> Hair count

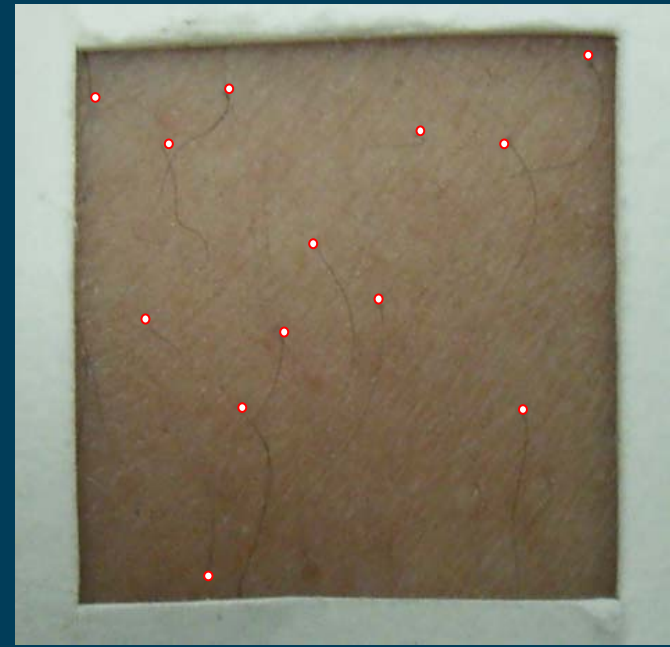
Tokyo Women's Medical University
Dr. Tezuka Dr. Wakamatsu

Before PPx Therapy



Forearm Hair Count Before: 31

After PPx Therapy



Forearm Hair Count 39 weeks after 2nd
Treatment: 13

> Hair count

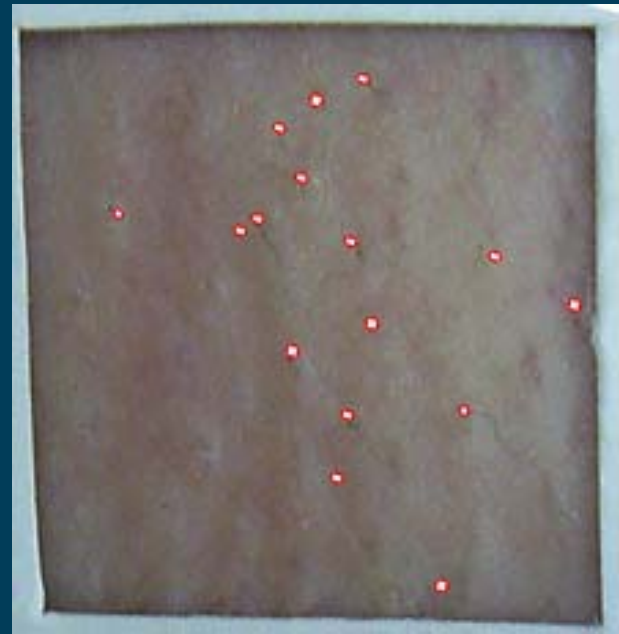Tokyo Women's Medical University
Dr. Tezuka Dr. Wakamatsu

Before PPx Therapy



Hair Count Before: 45

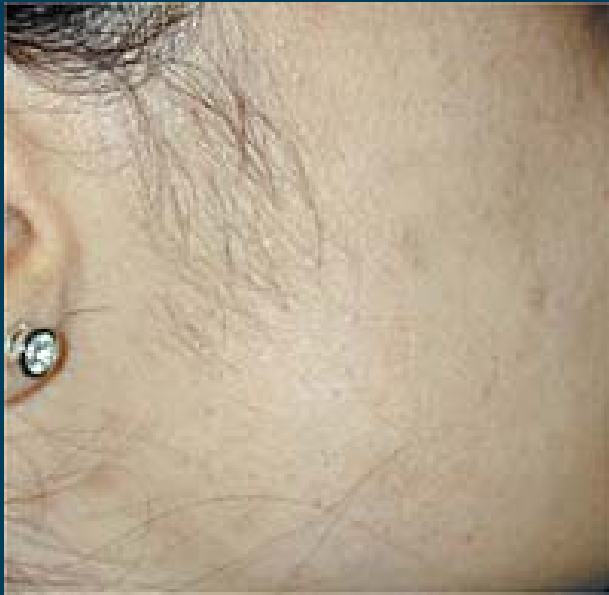After PPx Therapy



Hair Count 5 weeks after 3rd Treatment: 16

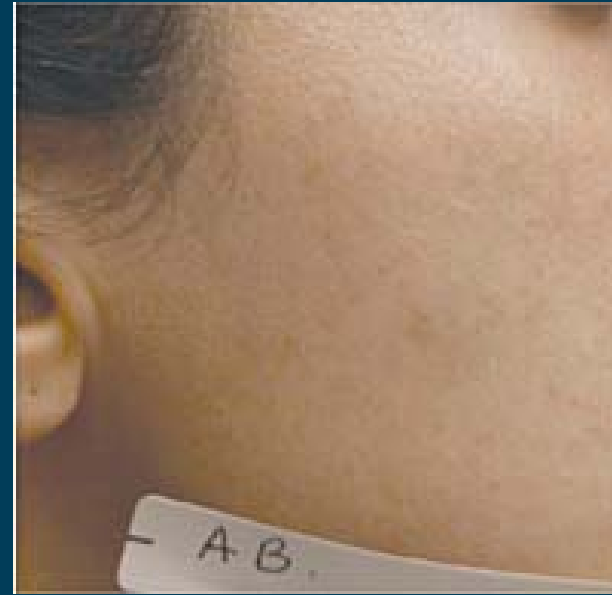> Clinical Outcomes - Hair Removal

Before PPx Therapy



Right Cheek before Treatment

After PPx Therapy

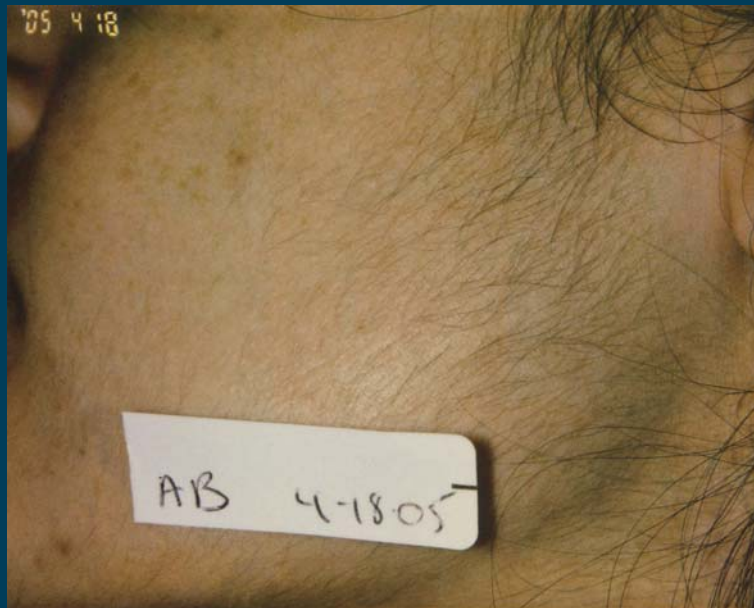


>120 days post 3rd Treatment

Photographs courtesy Dr. Vic Narurkar, San Francisco, CA

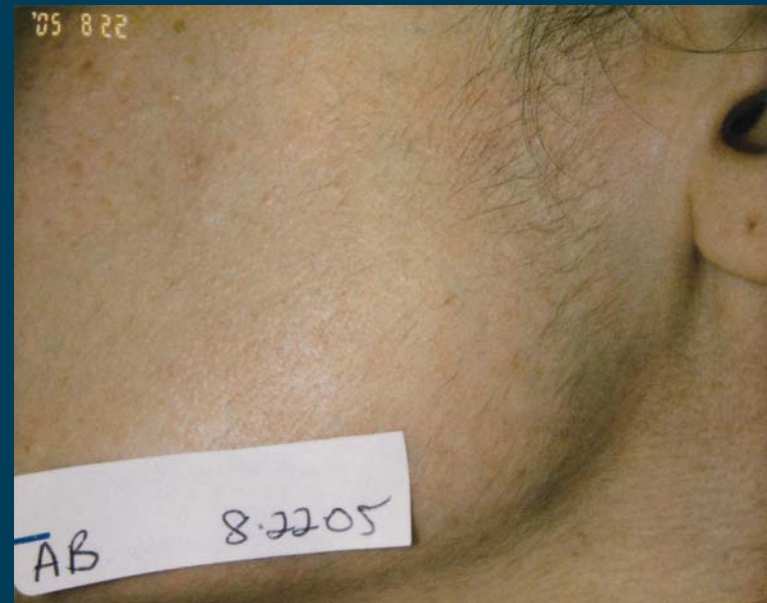> Clinical Outcomes - Hair Removal

Before PPx Therapy



Left Cheek before Treatment

After PPx Therapy

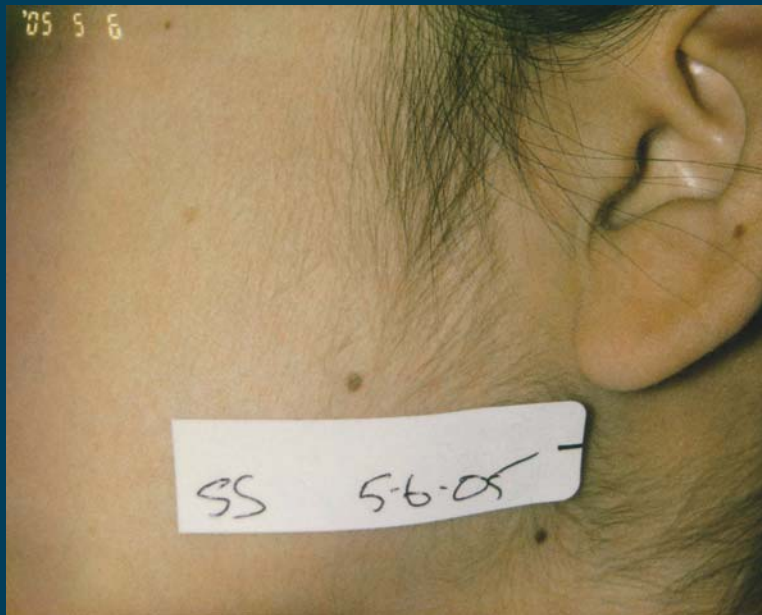

40 days after 3rd treatment

Photographs courtesy Dr. Vic Narurkar, San Francisco, CA

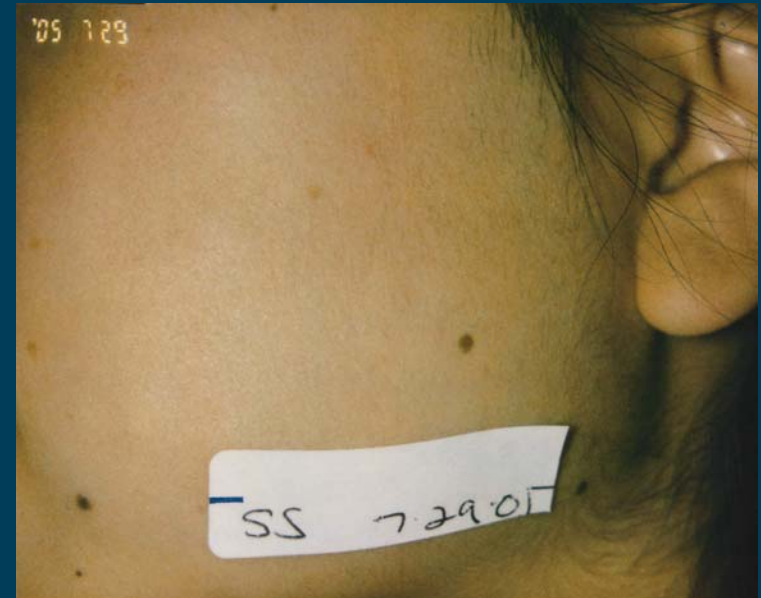> Hair Reduction – Vellus Hair

Before PPx Therapy



Right Cheek Before Treatment

After PPx Therapy



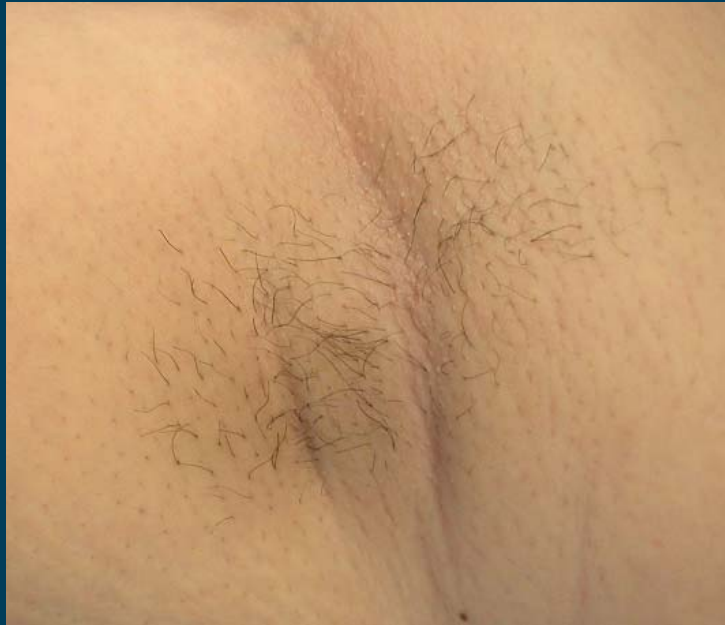After 2 treatments

Photographs courtesy Dr. Vic Narurkar, San Francisco, CA

> Clinical Outcomes - Hair Removal

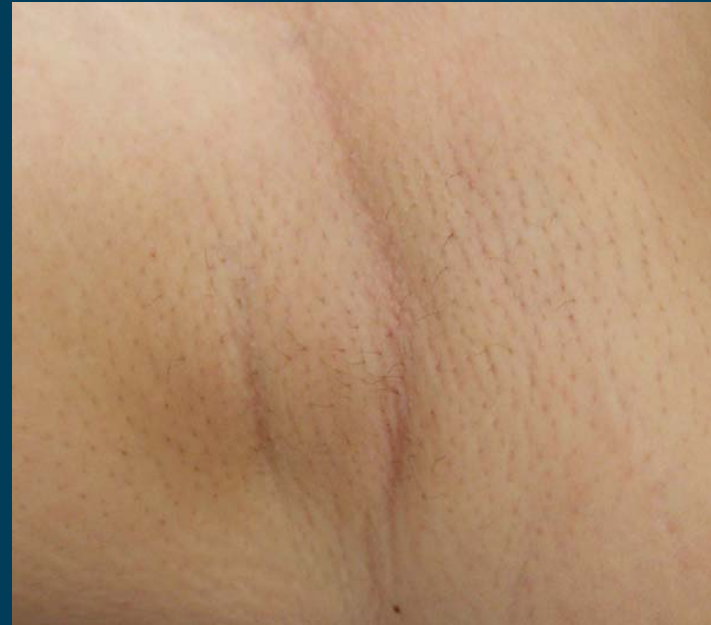Tokyo Women's Medical University
Dr. Tezuka Dr. Wakamatsu

Before PPx Therapy



Right Axilla Before Treatment

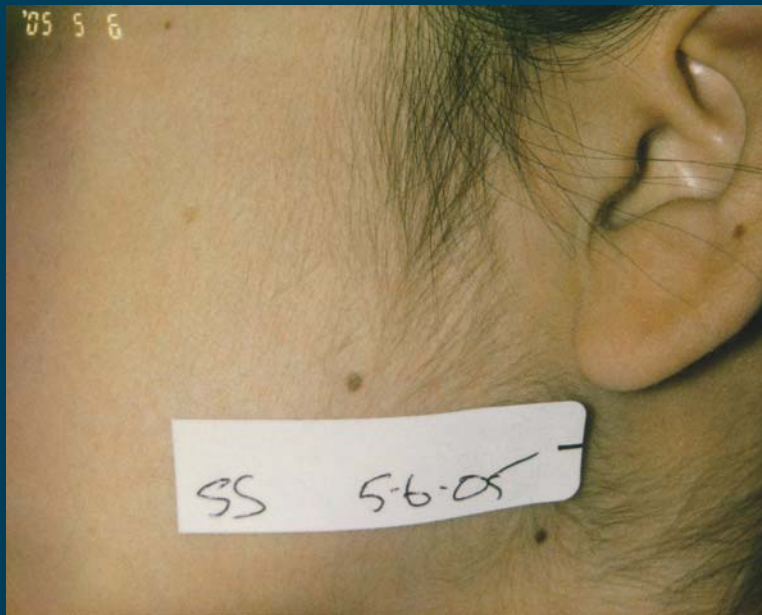
After PPx Therapy



6 weeks after 3 Treatments

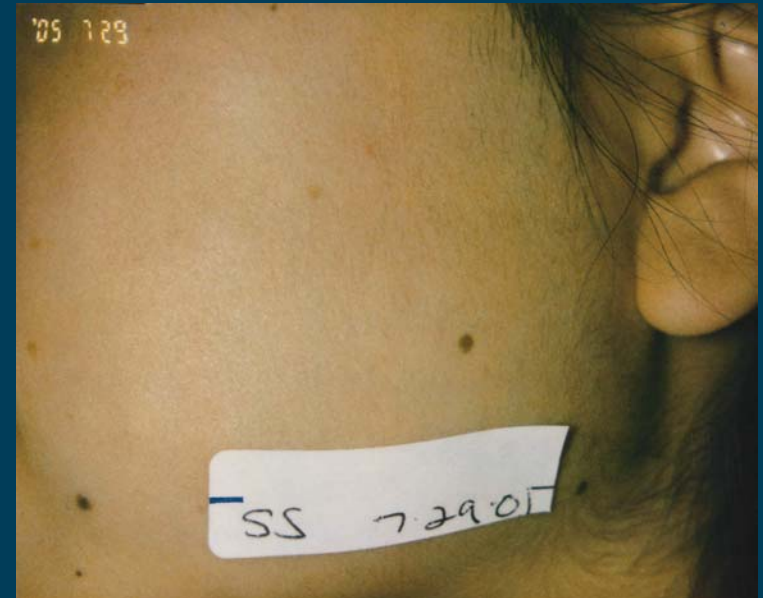> Hair Reduction – Vellus Hair

Before PPx Therapy



Right Cheek Before Treatment

After PPx Therapy

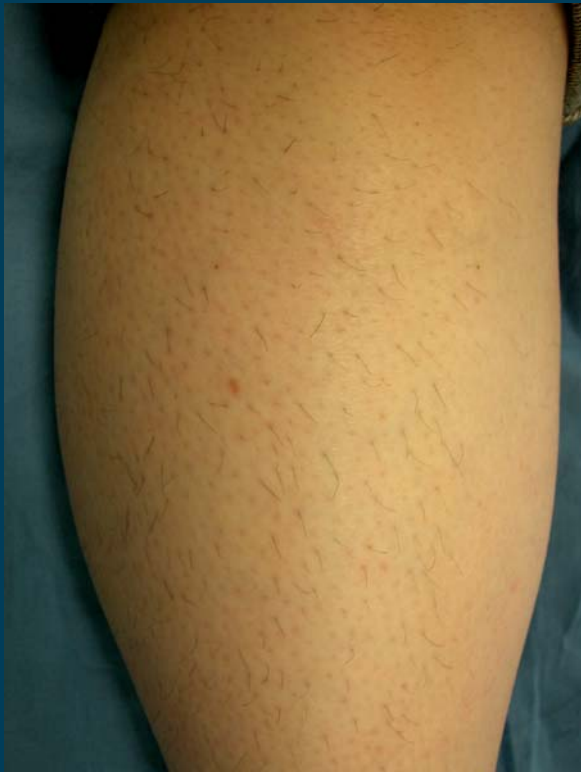

After 2 treatments

> Hair Removal - Leg

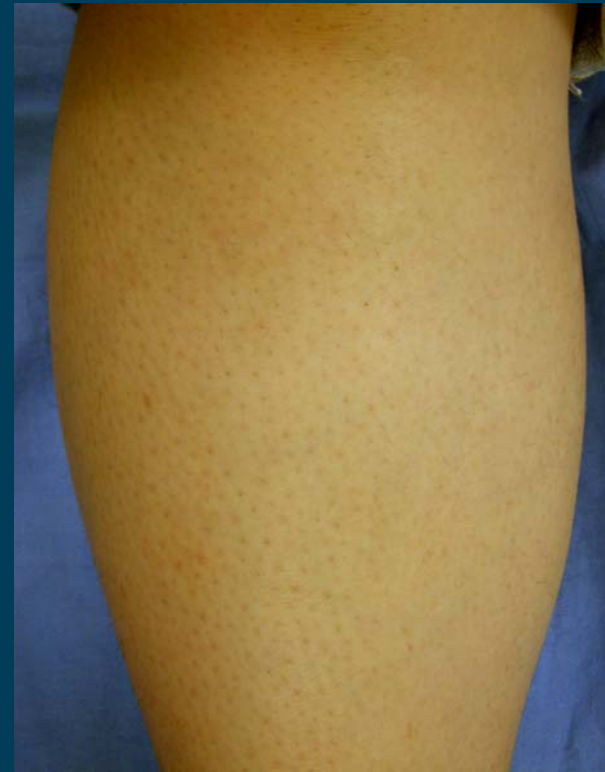Tokyo Women's Medical University
Dr. Tezuka Dr. Wakamatsu

Before PPx Therapy



Right Leg Before Treatment

After PPx Therapy

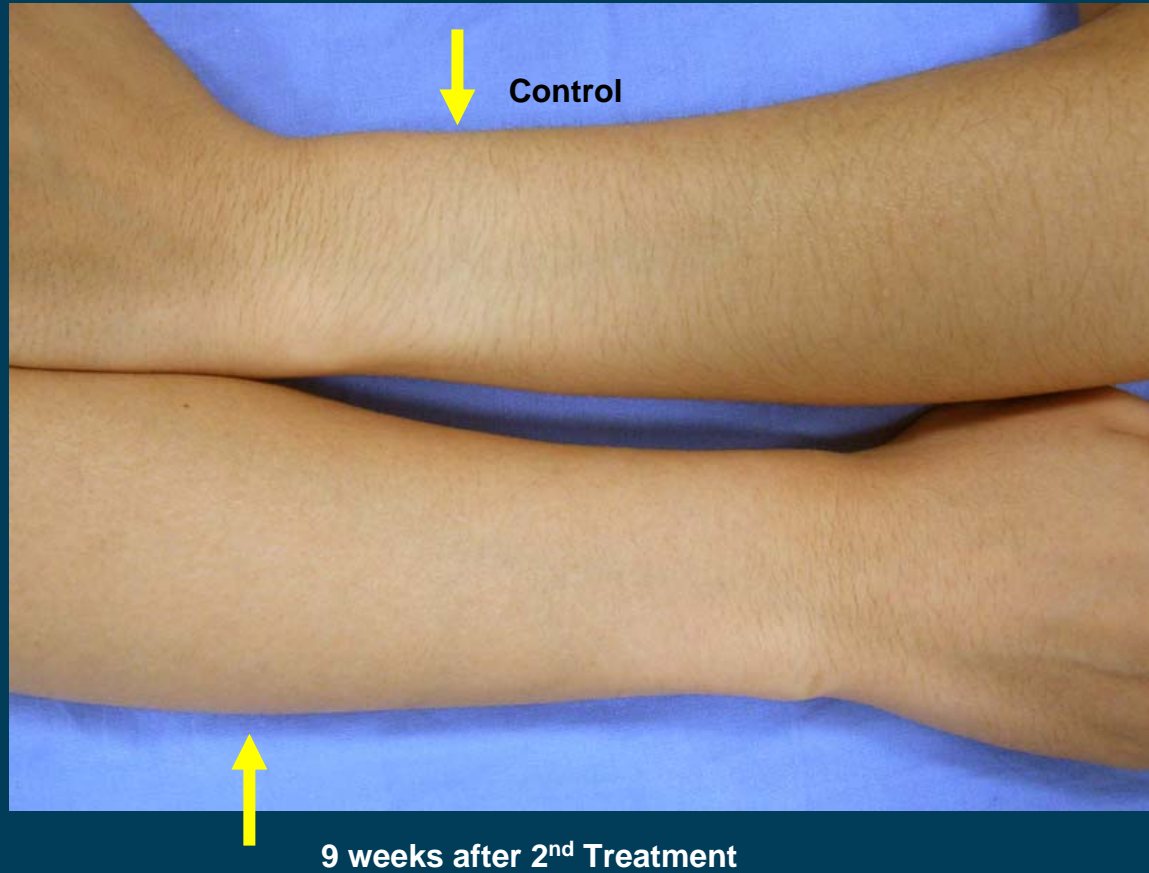


6 weeks after 3rd Treatment

> Hair Removal

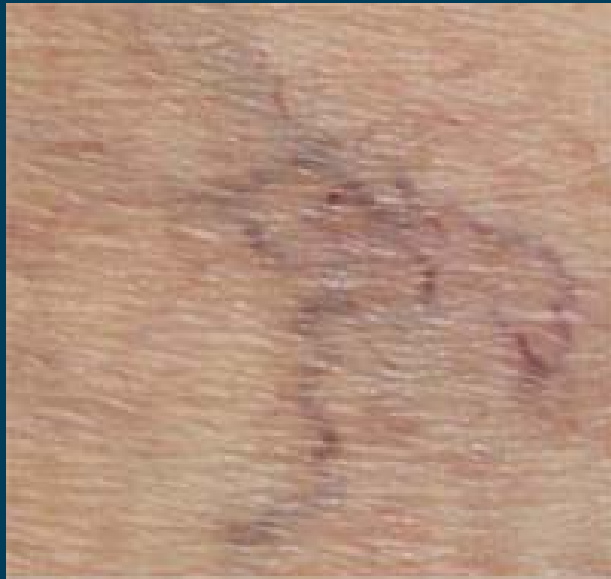
Forearm

Tokyo Women's Medical University
Dr. Tezuka Dr. Wakamatsu



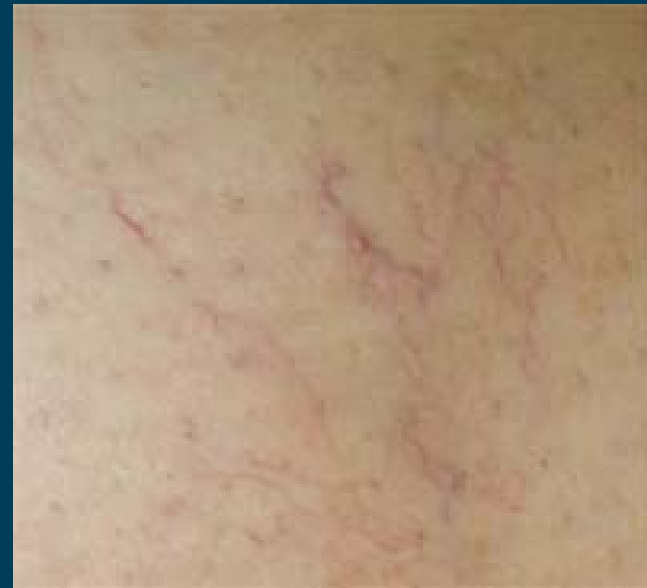> Clinical Outcomes - Vascular Lesions

Before PPx Therapy



Left Leg before Treatment

After PPx Therapy

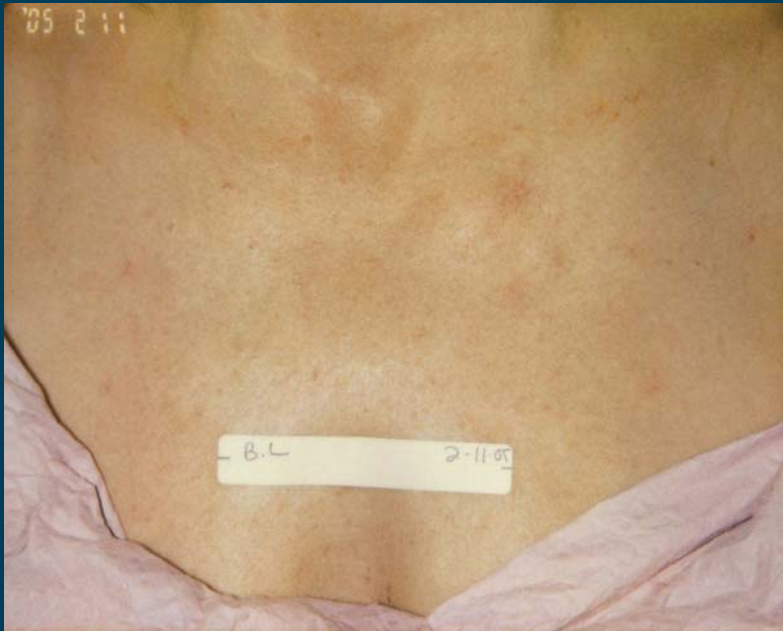

5 weeks post 2nd Treatment

Photographs courtesy Dr. Vic Narurkar, San Francisco, CA

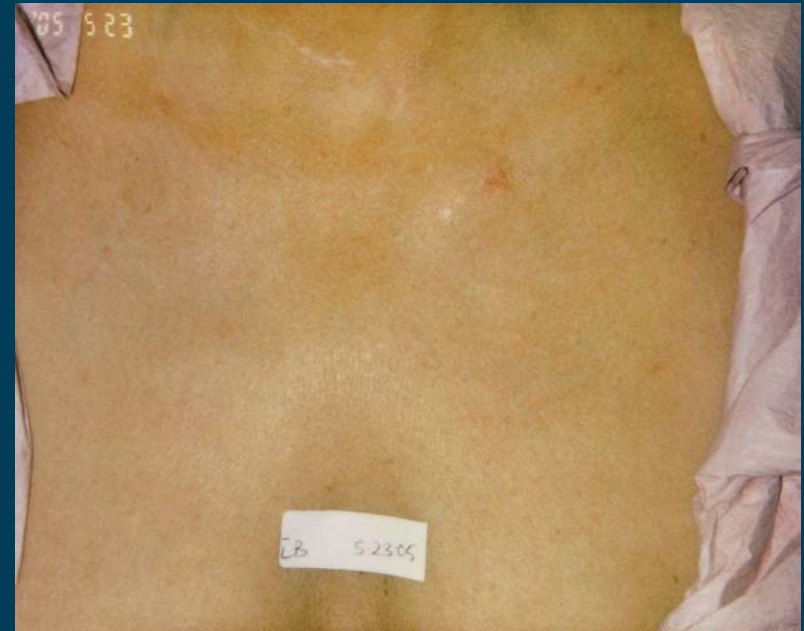> Clinical Outcomes - Vascular Lesions

Before PPx Therapy



Chest before Treatment

After PPx Therapy

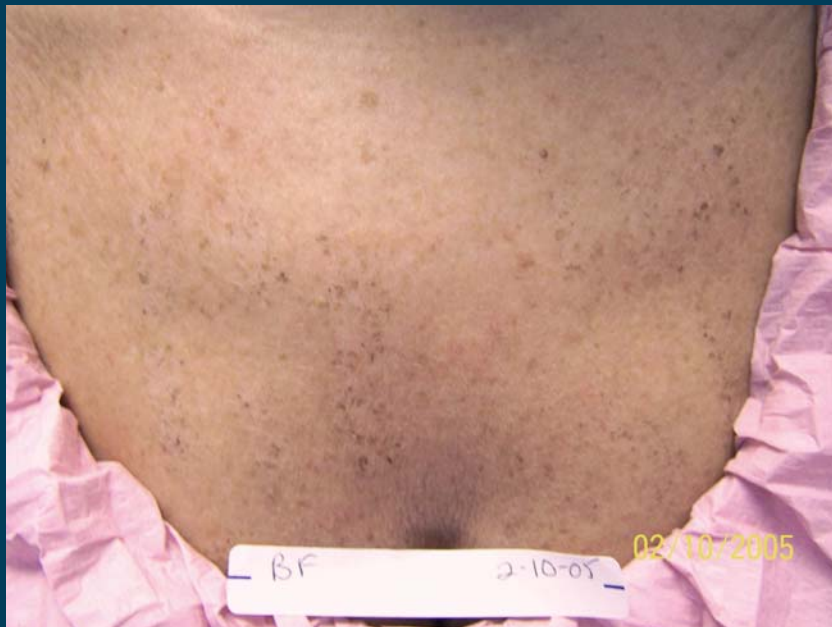

9 weeks after 3rd Treatment

Photographs courtesy Dr. Vic Narurkar, San Francisco, CA

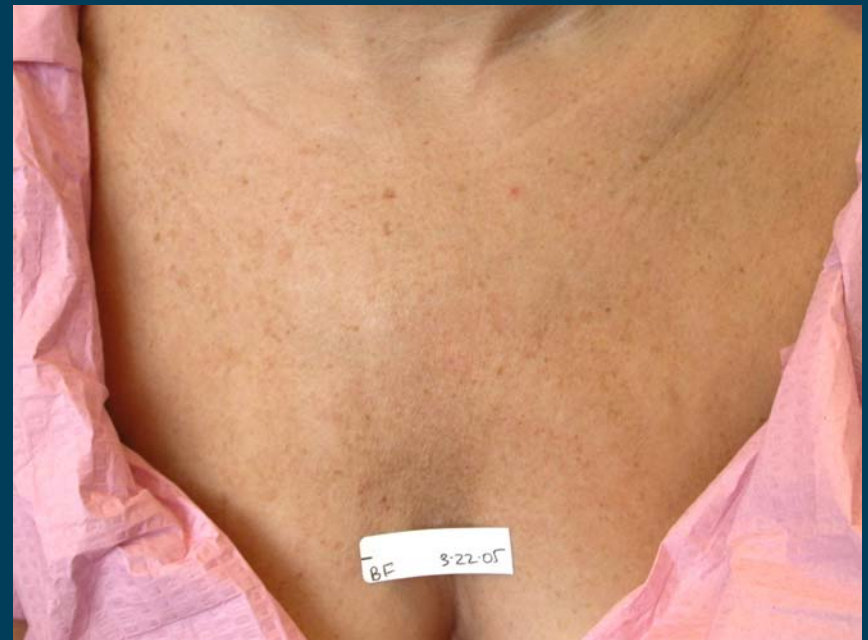> Clinical Outcomes - Pigmented Lesions

Before PPx Therapy



Chest before Treatment

After PPx Therapy

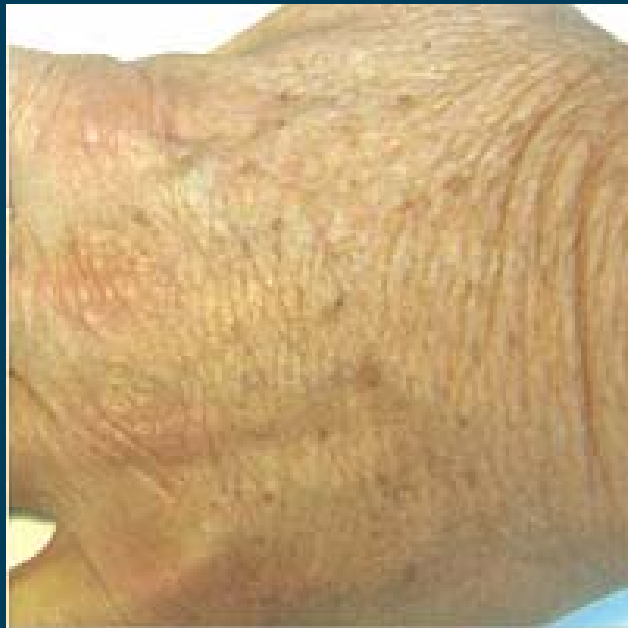

2 weeks post 2nd Treatment

Photographs courtesy Dr. Vic Narurkar, San Francisco, CA

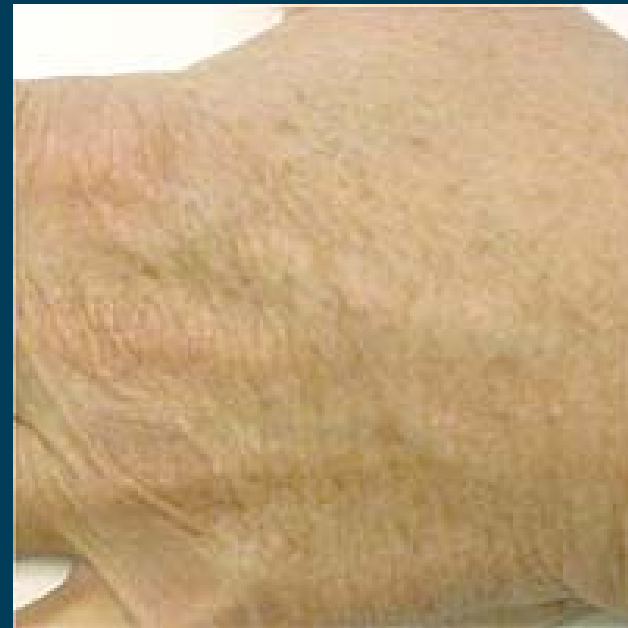> Clinical Outcomes - Pigmented Lesions

Before PPx Therapy



Left Hand before Treatment

After PPx Therapy

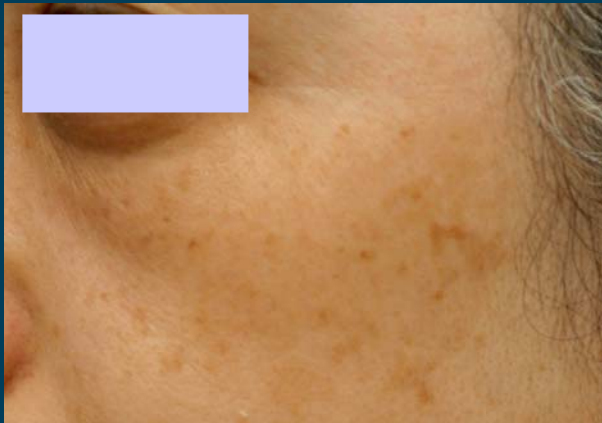

Left Hand post 2nd Treatment

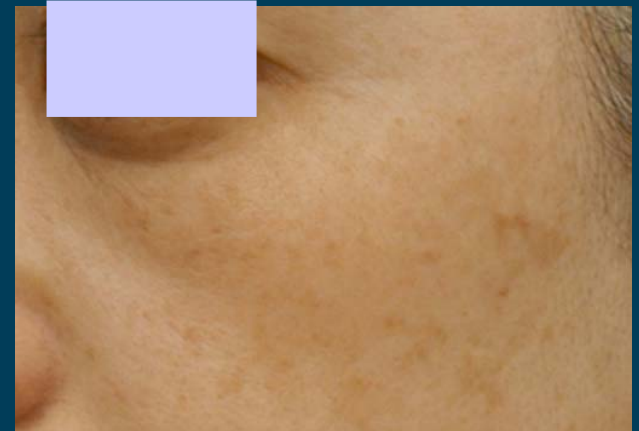Photographs courtesy Dr. Vic Narurkar, San Francisco, CA

> Clinical Outcomes - Pigmented Lesions

Tokyo Women's Medical University
Dr. Tezuka Dr. Wakamatsu



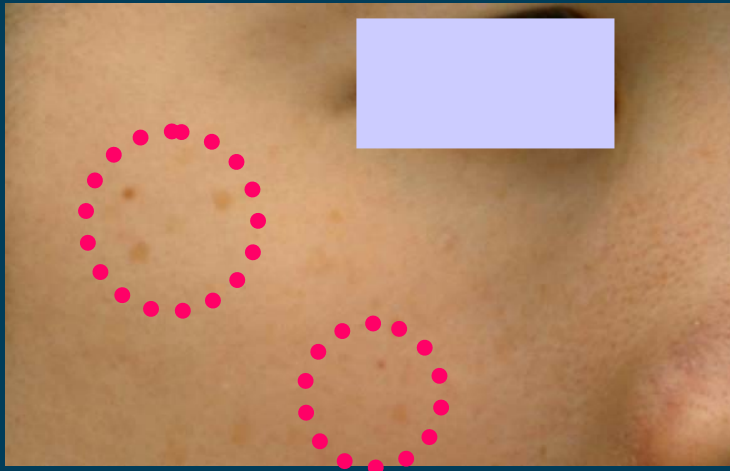Before



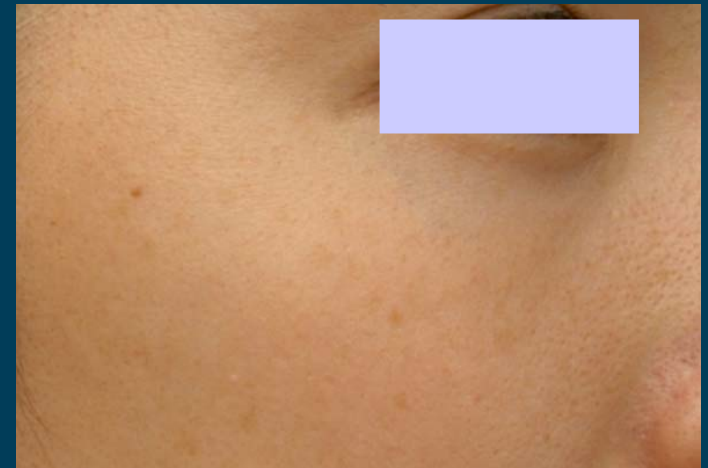After 3
treatments

> Clinical Outcomes - Pigmented Lesions

Tokyo Women's Medical University
Dr. Tezuka Dr. Wakamatsu

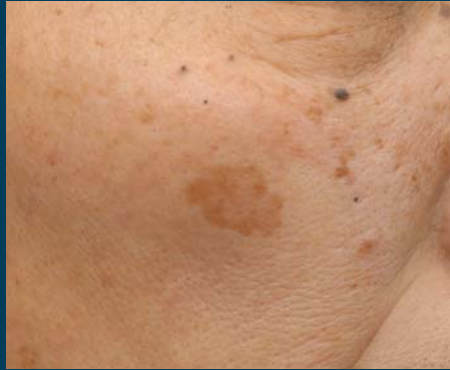

36-F Before

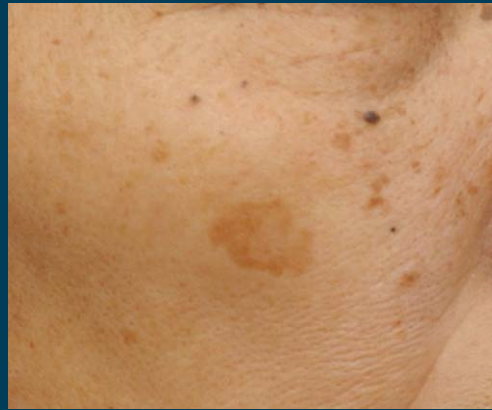

After 5 Treatments

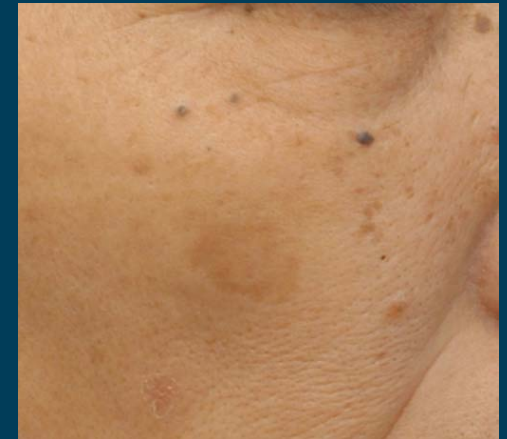> Clinical Outcomes - Melasma



68-F Before



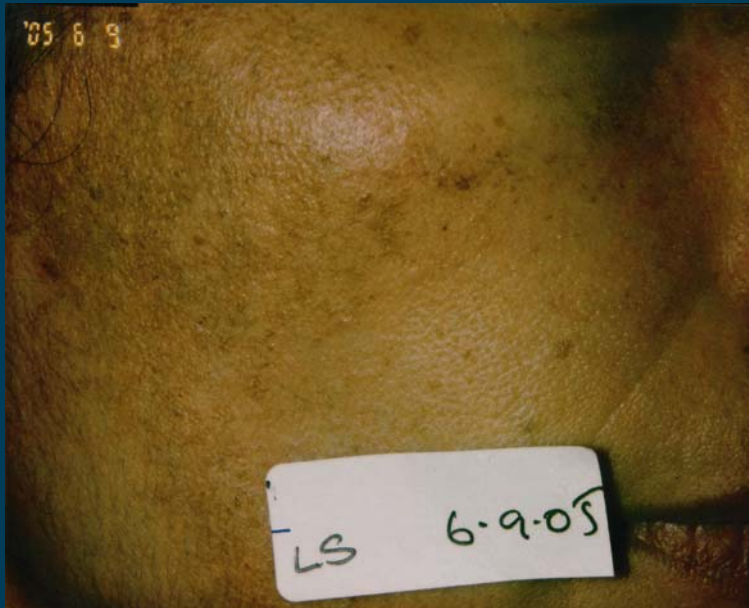After 2 treatments



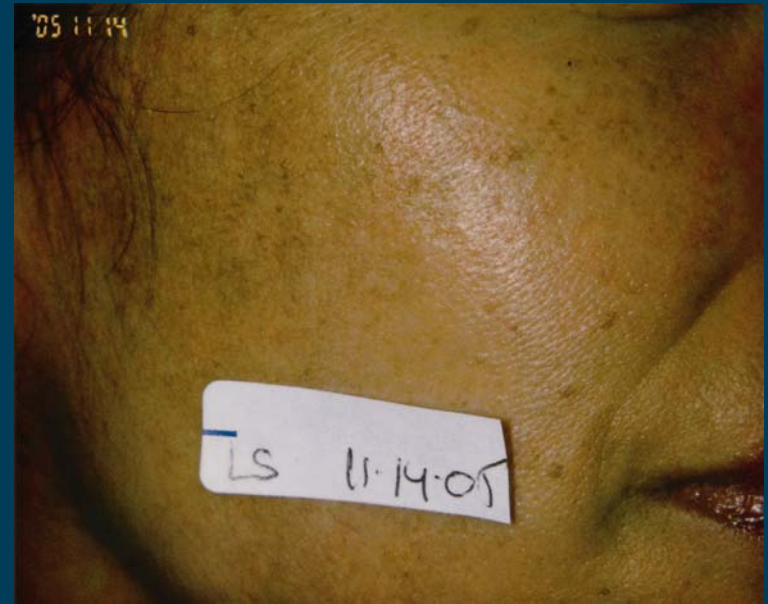
After 5 treatments

Tokyo Women's Medical University
Dr. Tezuka Dr. Wakamatsu

> Clinical Outcomes – Pigmented Lesions



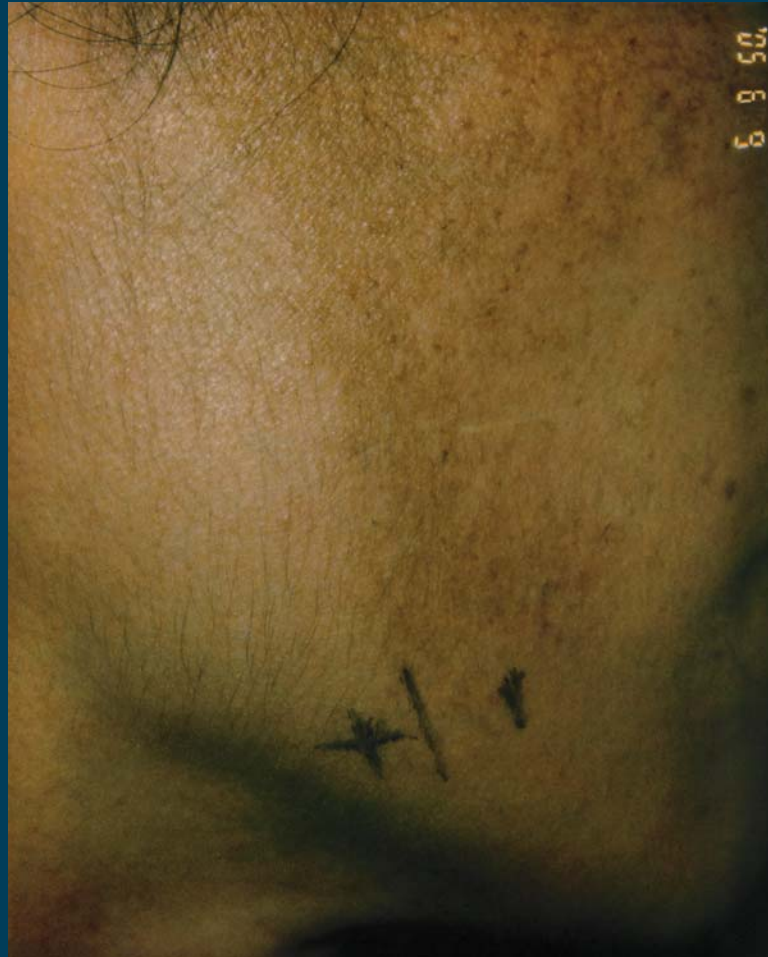Right Cheek – Before Treatment



100 days after 4rd treatment

Photographs courtesy Dr. Vic Narurkar, San Francisco, CA

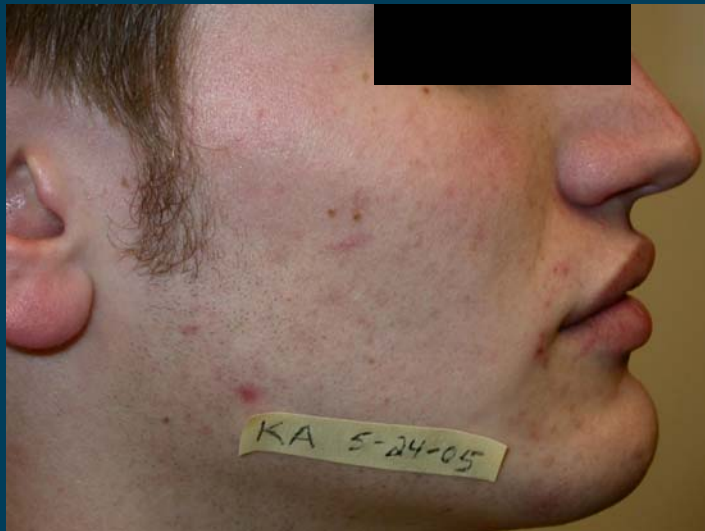> Clinical Outcomes - Pigment



After 3 treatments (+) Vs. Untreated Area (-)

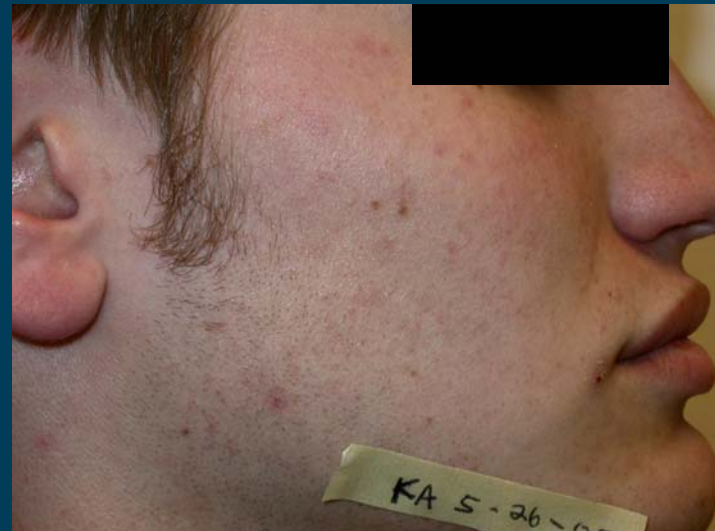> Clinical Outcomes - Acne

Before PPx Therapy



Right Cheek before treatment

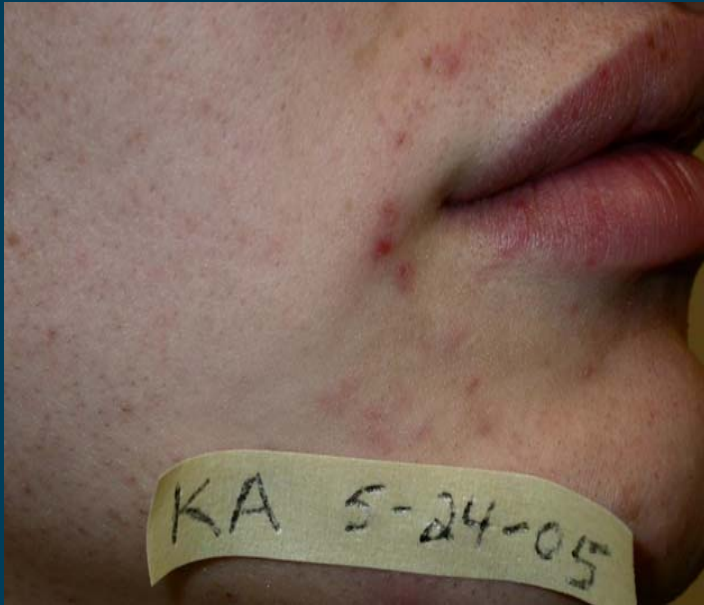After PPx Therapy



Right Cheek 2 days after 1st Treatment

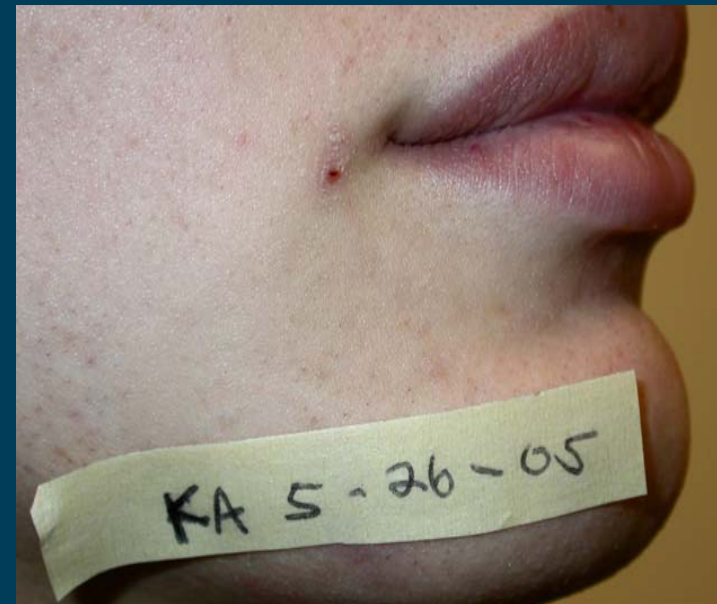> Clinical Outcomes - Acne

Before PPx Therapy



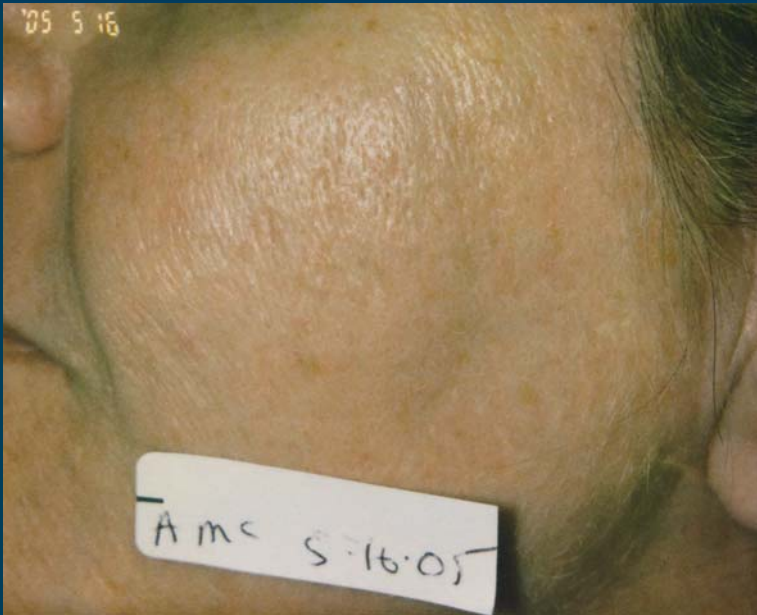
Right Cheek before treatment

After PPx Therapy

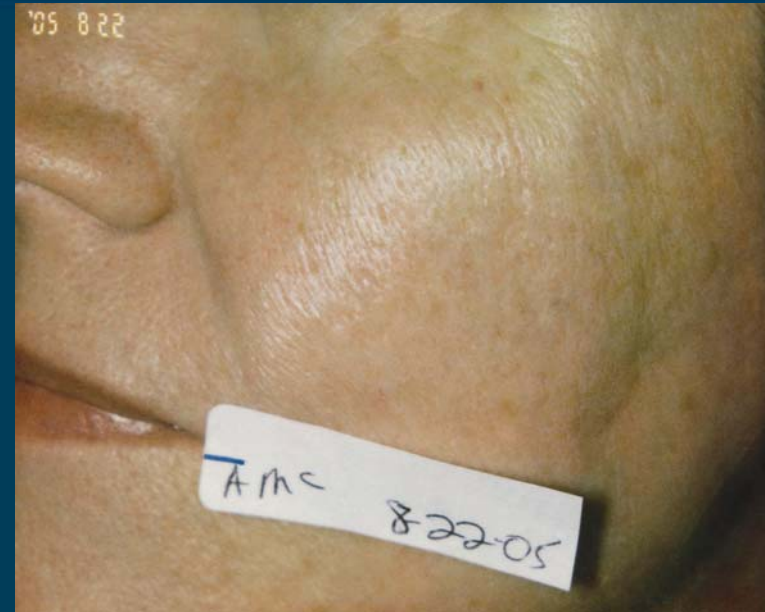


Right Cheek 2 days after 1st Treatment

> PPx Observations



Left Cheek before Treatment



Left Cheek after 3 Treatments

- Skin Tightening
- Pore size reduction
- Smoothness